

Definitions, History and General Considerations Related to the Aortic Aneurysms

Guillermo Careaga-Reyna

Chief of the Cardiothoracic Surgery and Cardiopulmonary Support Department,
UMAE, Hospital General "Dr. Gaudencio González Garza"
Centro Médico Nacional "La Raza", IMSS
Mexico

1. Introduction

The objective of this chapter is to present the definitions, history and general considerations related to the aortic aneurysm as an introduction to the other chapters of this book.

The aorta can be affected by a variety of pathological conditions as the aneurysms. Aneurysms are areas of dilation local or diffuse from the aorta. These aneurysms are developed in places of congenital or acquired weakness of the middle wall. Some of them have a clear genetic component and affect young patients. Most pathology is however encountered in the grown-up population and is caused by degenerative diseases (Risberg & Lönn, 2007)

2. History

2.1 Classic descriptions

Even when the aortic disease was described in the Egyptian papyri, the term aneurysm probably comes from the Greek *aneurysma*, which means enlarged or dilated (Cooley, 1999). The first description of an arterial aneurysm is attributed to Galen in the 2nd century. He wrote, "when arteries are enlarged, the disease is called an aneurysm". If the aneurysm is damaged, the blood drips into quarters, and is difficult to contain. In addition he described the difference between aneurysm caused by trauma and those caused by degenerative disease.

In the same 2nd century, Antyllus, developed and described a technique to treat these injuries. He believed that the clot seals the defect when there were dissection of the wall as well as try to ligation of artery above and below in thoracic aortic aneurysm and evacuated the clot.

In 1542, Fernelius told that the aneurysm originates as a result of thinning of the arterial wall, but is recognized that Vesalius made the first clinical diagnosis of an aneurysm in 1557 (Cooley, 1999; Kouchoukos NT, 1996).

In 1728, Lancisi published *De Motu Cordis et Aneurysmatibus*. In this paper it was proposed the etiology of abdominal aortic aneurysms. Later John Hunter showed that peripheral arteries can surely be ligated and Astley Cooper, one of his pupils, ligated an aneurysm of the aorta. These researchers believed that the ligation could decrease or stop the movement

of blood within the aneurysmal sac, which could cause thrombosis and eventually obliteration. Surgeons applied the ligature to the artery on the proximal side, the distal side, or both sides of the aneurysm. Ligation of aneurysms, however, returned to the extremities vulnerable to ischemic damage. Thus, the treatment of aortic aneurysms remained frustrating even for the best doctors. (Cooley, 1999)

In 1864, Moore inserted a wire of silver in a thoracic aneurysm to induce clot formation, and in 1879, Corradi applied a galvanic current through the wire. For 40 years, the method of combined electrolysis Moore-Corradi was adopted by other researchers. Blakemore and King, created a thermal coagulation device of aneurysms. The next step in the treatment of aneurysms was the stimulation of periarterial fibrosis. With this procedure, the cellophane or other types of plastic film were used as an irritant to cause occlusion of the vessel by tissue production. Harrison and Chandy applied this method to treat of the subclavian artery aneurysm, Poppe and De Oliveira used cellophane or plastic polyethylene films for wrapping aneurysms of the thoracic aorta produced by syphilis. In 1888, Dr. Rudolph Matas, developed a method for internal repair of aneurysms in which continuity of blood flow was restored by a simple intravascular suture of the artery opening directly the aneurysm sac. He described two procedures of aneurismorrhaphy. One called it the restorative, used for sacular aneurysms. In another technique -the reconstructive-, he excised the sick or injury portion of the vessel and created a tunnel through the remaining normal portion.

2.2 The twentieth century

In 1900, sir William Osler said, "There is no greater illness that leads to the clinical humility than aneurysms of the aorta" by the complexity and the limited treatment options and the outcome of the same.

In 1944, Alexander and Byron successfully resected an aneurysm of the descending aorta associated with aortic coarctation, but did not try to restore the aortic continuity.

In the same year, Ochsner treated a small sacular aneurysm of the descending aorta with good results.

On 28 April 1950, Denton A. Cooley conducted its first surgical treatment of aortic aneurysm, and in 1951, reported a work entitled "Surgical considerations of intrathoracic aneurysms of the aorta and large vessels". Gross and his colleagues, began the modern era of vascular grafts and employed preserved homografts to treat aortic coarctation (Cooley, 1999).

Those aneurysms that appears large in radiological studies, thin-walled and adhesions to the posterior side of the sternum recommended that before doing the surgical approach via median sternotomy, a left lateral thoracotomy was conducted to put a cannula to decompress the left ventricle. This maneuver to empty the heart, decreases the tension within the aorta, and in case of rupture when the sternum was opened, represents support in aspiration and control of bleeding.

In 1956, Cooley and DeBakey described a technique for the replacement of the ascending aorta with a synthetic graft distal to the coronary arteries ostia. In 1960, Mueller et al. combined the replacement with a supracoronary graft and the bicuspidization of an incompetent aortic valve. In 1963, Starr and collaborators described a replacement with a supracoronary graft and replacement of the valve.

In 1964, Wheat and colleagues described a radical technique of resection of the aortic wall, carrying the small buttons of adjacent tissue to the coronary ostium, replacement of the

aorta with a graft, and prosthetic aortic valve replacement. In 1968, Bentall and Bono described a technique for replacement of the ascending aorta and aortic valve with a tubular graft containing a valve prosthesis with latero-terminal reimplantation of the ostium of the coronary artery graft. This technique reduces the risk of recurrent proximal aortic aneurysm. (Kouchoukos, 1996; Gelsomino et al., 2003).

In the following decades (1970s, and early 1980s), the results of thoracoabdominal aortic aneurysm and descending thoracic aortic aneurysm repair were extremely different from center to center. (Safi, 2007).

Until the development of vascular grafts, prosthetic valves and the improvement of extracorporeal circulation techniques, surgical treatment of aneurysms of the ascending aorta was limited to the plication of the aorta or aneurismorrhaphy (Gelsomino et al., 2003)

Graft prosthetic, valved conduits or procedures with placement of an endovascular graft within the site of the aneurysm are currently used. (Cooley 1999; Gelsomino et al, 2003; Saiki et al., 2003; Girardi et al., 2002)

Traditionally the gold standard treatment has been surgery with a short-term treatment mortality incidence of 10-20% for elective procedures. In recent years, endovascular aortic repair of descending aneurysms has shown great promise. In 1991 Volodos and his group published the first report on endovascular stent grafting for a thoracic aortic lesion (Volodos et al, 1991), while the clinical first series was published by the Stanford group in 1994 (Dake et al, 1994)

The first endovascular thoracoabdominal aneurysm operation using branched grafts was reported by Chuter in 2001 (Chuter et al, 2001)

3. Classification

In the last decade, the descending thoracic aneurysms were classified only based in the aortic extension they affect: The upper half, lower half, or entire thoracic aorta, named as types A, B, and C, respectively. During the clamp-and-sew technique, it was showed that the maximum incidence of neurological deficit involved types B and C. Safi and coworkers consider these using the modified "Crawford classification," (table 1) (Safi, 2007).

Type	Description
Extent I	from the left subclavian artery to above the renal arteries
Extent II	from the left subclavian artery to below the renal arteries
Extent III	from the 6th intercostal space to below the renal arteries
Extent IV	involves the total abdominal aorta from T12 to below the renal arteries
Extent V	from the upper extent of the 6th intercostal space to the lower extent above the renal arteries

Table 1. Modified crawford classification

It was found that the extent of the aneurysm correlated with a high incidence of neurological deficit (31%), the highest being in extent II. In the clamp-and-sew technique, the clamp time and the extent of the aneurysm correlated to neurologic deficit (Svensson et al. 1993).

In regards to the aortic dissections present the classification of DeBakey (table 2), and in table 3 the Stanford proposed by Daly et al in 1970 (Kouchoukos, 1996; David TE, 1997; Kato et al., 2002).

Type	Description
(I)	The tear of the intima usually originates in the proximal ascending aorta and extends to the ascending aorta, aortic arch, and variable-length to the thoracic aorta descending and abdominal.
(II)	The dissection is limited to the ascending aorta.
(III)	Dissection can be limited to the descending thoracic aorta (type IIIa) or extended proximally and affect the ascending aorta and aortic arch.

Table 2. DeBakey's classification for aortic dissection.

Type	Description
A.	It includes all the dissections involving the ascending aorta, regardless of their place of origin and its extension, corresponds to the types I and II of De Bakey.
(B)	It includes the dissections in the ascending aorta is not affected, this corresponds to the type De Bakey III

Table 3. Stanford classification for the aortic dissections.

4. General concepts

Aneurysms are characterized by degeneration of the media resulting in a weakness of all the layers of the aortic wall. Its recognized that 50% of the thoracic aneurysms are originated in an aortic dissection. These are truly pseudoaneurysms since not all layers of the aortic wall are engaged. (Bickerstaff et al. 1982).

Once expressed, the formation of the aneurysm is progressive because some level of intraluminal pressure and tangential wall tension, increases with the square of the radius and are described as the aneurysms sac.

The risk of rupture is related to the largest diameter of aorta with a fatal outcome in 33-50% of the patients, while comorbidities are responsible for the remaining deaths (Bickerstaff et al. 1982; McNamara et to 1978).

In many cases, based in clinical findings and comorbidities, regular observation and medical management are indicated, but surgical treatment has been recommended if the sac diameter of the aneurysm reaches 5.5 cm even for asymptomatic cases (Lederle et al., 2007), but the criteria has been modified due to the higher risk of rupture with a great diameter; and in symptomatic aneurysms, immediate treatment is required, regardless of diameter.

If we find an aneurysm with a diameter of over 3 cm it must be monitored with ultrasonography every 12 months. When the diameter of the aneurysm has reached 5 cm in a man or 4.5 cm in a woman the ultrasonographic checks are carried out every 6 months (Powell & Greenhalgh, 2003).

Hypertension and other cardiovascular risk factors should be treated effectively. The systolic blood pressure should be lowered quickly to around 100- 120 mmHg. First aid treatment includes chewed antihypertensive drugs (i.e nifedipine), nitrate (or nitroprusside) infusion to beta-blocker, and effective analgesia.

The mortality from a ruptured aneurysm is 90%. Also, the surgery is a priority in patients with symptoms that suggest expansion or compression of an adjacent structure.

Short-term mortality for stent grafting of the aorta for aneurysms and type B dissections are less than for open surgery (Lepore et al., 2002; Lönn et al. 2003).

The aim of endovascular aortic repair is to prevent rupture of the aneurysm sac by its exclusion and decrease of the pressure on the wall of the aneurysmal sac stress, or to reduce the pressure in the false lumen with subsequent obliteration. Now with the new improved stent grafts for thoracic use. The endovascular procedure may increase its application as less invasive than standard operative repair and patients who were previously not eligible for surgery may now be considered for treatment, with lower risk than open surgery.

4.1 Thoracic aorta aneurysms

About 20% of the aortic aneurysms are located in the thoracic aorta (Bickerstaff et al. 1982).

The etiology for the thoracic aneurysms do not differ in any segments of the aorta. They can be due to degeneration, medial noninflammatory atherosclerotic degeneration, chronic dissections, trauma or infectious diseases (mycotic or syphilitic). The most common connective tissue disorder associated with aneurysm is the hereditary disorder Marfan's Syndrome. More rarely, Klipper-Feil syndrome or Turner's syndrome among other syndromes may involve the aorta (Kouchoukos, 1996; David, 1997; Greenberg & Rischer, 1998)

Aneurysms of the thoracic aorta are typically those that affect the aortic ring and ascending aorta (Figure 1), aortic arch or descending aorta. (Von Fricken, 2002).

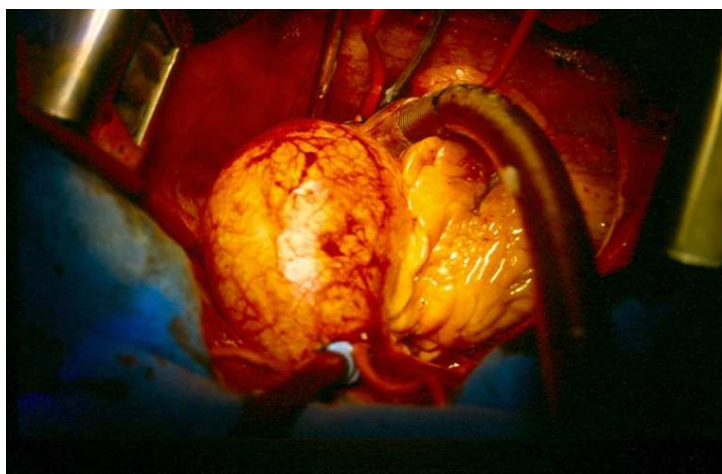


Fig. 1. Aneurysm of ascending aorta without extension to supraaortic branches.

There is a pathological disorder which precedes the formation of an aneurysm in the thoracic aorta in 60% of the cases is the dissection. (Kouchoukos, 1996; Von Fricken, 2002; Kato et al., 2002)

In regards to our experience, the frequency by gender was higher in the male than the female, similar to that reported in the literature. (Ramirez-Vargas et al., 2003; Miyairi et al, 2002; Colombi et al, 1983; Cabrol et al, 1986; David & Feindel, 1992)

Early population-based studies have been demonstrated to 5-year survival rate for untreated thoracic aneurysms of only 13 per cent (Bickerstaff et al. 1982), and for patients with degenerative aneurysm 3-year survival was 35% (McNamara et al. 1978).

Usually thoracic aortic aneurysms are asymptomatic. So if pain appears, suggests expansion, equal as tracheal or bronchial compression. Sometimes the neck veins are dilated due to the compression caused by the aneurysm.

The thoracic aortic aneurysms may be visible as an incidental finding on a chest x-ray film, but improved diagnostic accuracy and more frequent use of CT and echocardiography accounts for the relative increase in the frequency of aortic aneurysms. Transoesophageal echocardiography is a good primary investigation. Computed tomography, magnetic resonance imaging (MRI), or angiography is often needed for final diagnosis.

The risk for rupture during a 5-year period for thoracic aneurysms was near 20%; and in women was greater than men with a 7:1 ratio (Johansson et al, 1995; Meszaros et al, 2000). However this pattern may differ as Johansson et al. demonstrated when in Scandinavia found an equal sex distribution in ruptured thoracic aneurysms (Johansson et al. 1995).

Aortic valve insufficiency is of particular concern in the ascending aorta aneurysms. This risk is proportional to the increase in size of the aneurysm and on this basis, are new recommendations for an earlier surgical treatment with lower diameters than previously accepted.

The preoperative assessment of coronary mouths or the aortic valve disease is very important to choose the appropriate surgical procedure. The decision to treat an aneurysm should be based on the risk of rupture and the life expectancy of the patient (Greenberg & Rischer, 1998)

On the other side the aneurysms of the descending aorta have an incidence of approximately 30-50/million inhabitants/year (Joyce et al. 1964).

Repair for the ascending aorta aneurysms is an open standard replacement of the diseased segment of the aorta and if needed combined with a new valve insertion and reattachment of the coronary arteries with a synthetic valved aortic graft as shown in figure 2 (Gelsomino et al., 2003; Cabrol et al, 1986; Carias de Oliveira et al., 2003).

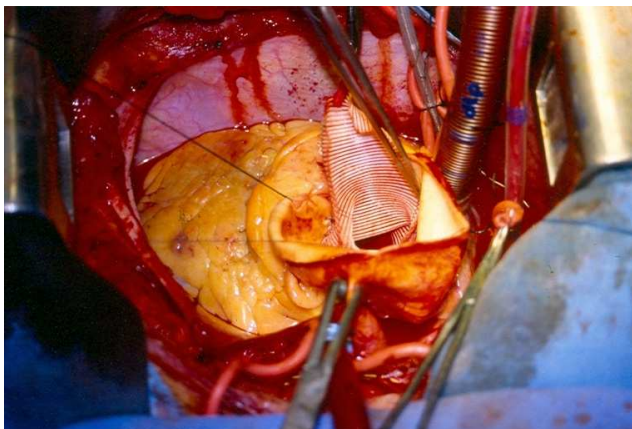


Fig. 2. Surgical treatment of an aneurysm of the ascending aorta with a mechanical valved graft.

Although important progress in surgical methods, brain preservation and myocardial protection and the postoperative care, often the surgical treatment of thoracic aortic aneurysms remains a challenge for the cardiothoracic surgeon (Greenberg & Rischer, 1998).

The surgical treatment of aortic aneurysm may be associated to another procedures: myocardial revascularization, implant for mitral valve prosthesis, correction of coarctation of the aorta or closure of an atrial septal defect, as we reported (Ramirez-Vargas et al., 2003). Other publications have also referred surgical procedures combined with the treatment of aneurysms of the thoracic aorta as tricuspid valve surgery and closure of the interventricular septal defect (Schulte et al, 1983; Massih et al, 2002; Levine et al. 1968).

In our experience, the time of aortic cross clamping and cardiopulmonary bypass give a similar average result compared to other series (Ramirez-Vargas et al., 2003; Kouchoukos, 1996; Gelsomino et al., 2003; David & Feindel, 1992; Tominaga et al., 2003).

The main type of cardioplegic solution was St. Thomas in 88.5% and only 11.5% was used HTK solution. Oster and cols, employed HTK for myocardial protection in a study with good results (Oster et al, 1983).

Several options have been used to reduce the incidence of neurological and renal complication which include: circulatory arrest with deep hypothermia, selective antegrade cerebral perfusion, retrograde cerebral perfusion, drainage of cerebrospinal fluid, placement of ice on the head in patients undergoing aortic arch surgery mainly (Ramirez-Vargas et al., 2003; Girardi et al, 2002; Oster et al, 1983; Di Eusanio et al., 2003; Griep, 2003; Bachet et al, 1999; Deeb et al, 1999; Dossche et al., 1999).

The most commonly used approaches include the median sternotomy for treatment of aneurysm in the aortic arch. There are others such an "L" incision, with an incomplete median sternotomy and a previous thoracotomy is performed giving a greater advantage in the visualization of the surgical field and all the advantages that this leads well as its main disadvantage is the pain of the wound. For the approach of the distal aortic arch and descending aorta is preferred a postero-lateral thoracotomy (Gelsomino et al., 2003; Kay et al, 1986; Colombi et al, 1983; Tominaga et al, 2003; Kazui et al, 2002; Levine et al, 1968)

Femoral cannulation for cardiopulmonary bypass, remains the standard option for surgical repair of acute aortic dissection type. However, the retrograde perfusion has the potential risk of embolization of detritus of atheroma, extension of the dissection and poor perfusion (David & Feindel, 1992; Ergin et al., 1999). We use in 20.5% of this pathology femoral artery cannulation (Ramirez-Vargas et al., 2003). Other sites for cannulation have been described. One of this is the axillary artery which has the advantage for heart operations performed with cardiopulmonary bypass in the presence of occlusive peripheral disease, atherosclerosis of the femoral vessels, or distal extension of dissection (Careaga et al, 2001; Oberwalder et al., 2003; Murray & Young, 1976; Ergin et al, 1999; Galajda et al., 2003; Minatoya et al., 2003; Karmy-Jones et al, 2001)

Hospital-acquired early postoperative mortality has been reported by 4% to 20%. We had an early postoperative mortality of 7.7%. The main causes were perioperative myocardial infarction, left ventricle failure with low cardiac output, acute dissection, shock, hemorrhage (Ramirez-Vargas et al, 2003; Kouchoukos, 1996; Gelsomino et al., 2003; Girardi et al, 2002; Cabrol et al, 1986; Di Eusanio et al., 2003; Bell et al., 2003; Kay et al, 1986).

Other consideration is the association of aortic aneurysm and coarctation is a known entity. Aortic artery may become occlusive in the site adjacent to who has the greater narrowing as a result mainly of haemodynamic effects, dissection or aneurysm inflammatory or infectious. (Kouchoukos et al, 2003)

It is rare in children because the total of aneurysms prevalence increases as the individual grows, so that it approaches 20% when the patient is in the final stages of the third decade of life (Schuster & Gross, 1962)

The formation of aneurysms may be a late complication of a surgical repair or endovascular, but is less frequent in the absence of corrective procedures. Aneurysms are most frequent in intercostal arteries and can be isolated or multiple and followed in order of frequency by the aortic segment located after a coarctation, aortic and finally into the left subclavian artery isthmus (Kouchoukos et al, 2003).

Coarctation of the aorta-surgical treatment has provided successful mostly in the last decade. (Kouchoukos et al, 2003; Schuster & Gross, 1962; Parks et al, 1995; Bell et al., 2003).

The formation of aortic aneurysms associated with coarctation of the aorta is rare (Parks et al, 1995; Bell et al., 2003)

There are currently endovascular techniques for the correction of aortic aneurysms associated or not to aortic coarctation. However, in this association the recommended procedure is open surgery (Bell et al., 2003; Knyshov, 1996)

4.2 Abdominal aneurysms

The incidence of rupture of abdominal aortic aneurysms is estimated to be 9.2 cases per 100,000 person-years (Bengtsson & Bergqvist, 1993). Ruptured aortic aneurysms remain the 13th leading cause of death in the United States with an increasing prevalence (Coady et al., 1999); This may be attributable to improved imaging techniques, increasing mean age of the population, and overall heightened awareness (LaRoy et al, 1989).

Due to the age profile of the patients, atherosclerotically damaged vessels in one or several organs increase the risk of complications for surgical treatment of this patients as pulmonary disease, reduced FEV₁, renal, abdominal and cardiovascular complications, which contribute to a significantly increase of morbidity. However all symptomatic patients need immediate surgery. We must remember that about 30% of the patients have clinically significant cardiovascular, stroke, renal, or peripheral atherosclerotic disease.

The mean age of this population is between 59 and 69 years with a male to female ratio of 3:1 (Bickerstaff et al. 1982). Branched devices have incorporated side branches and their use is for those aneurysms with no neck/proximal landing zone at all. These advanced devices can be classified according to target region (abdominal or thoracic or thoracoabdominal) and subdivided into fenestrated or branched stent-graft systems (Melissano et al, 2004; Verhoeven et al., 2005).

4.3 Thoracoabdominal aortic aneurysms

On the other side the thoracoabdominal aortic aneurysms (TAA) constitute about 10-15% of all aortic aneurysms. This type of aneurysms are probably the most difficult to treat. Chronic dissection is the cause of these aneurysms in approximately 20% of the cases (Svensson et al. 1993).

Women seem affected as often as men which is at variance with abdominal aneurysms which predominantly are to male disorder. So, the 85% of the patients are men for the abdominal aneurysms and 10 per cent of men are aged 75 years or more.

In the table 1, present the Crawford classification for the thoracoabdominal aneurysms according to their size. Type II aneurysms are the most extensive and difficult to treat. They also have the highest morbidity and mortality.

Modern treatment of TAA was pioneered by Stanley Crawford who introduced the "inlay" - technique (Crawford, 1974).

Type	Description
(I)	Descending aorta + part of visceral branch
(II)	Descending aorta + abdominal aorta
(III)	Distal part of descending aorta + abdominal aorta
(IV)	Visceral branches

Table 1. Crawford classification of thoracoabdominal aortic aneurysm

By using motor evoked potential to monitor motor function of the spinal cord during surgery the risk for paraplegia can be reduced further to around 2% (Jacobs & Mess, 2003). Preventive measures must be largely preoperatively, such as coronary artery by-pass grafting or percutaneous coronary interventions, and a proper risk assessment must be performed.

The most frequent risk factors of aortic dissection are degenerative disease of the middle and high blood pressure (Oberwalder et al., 2003).

In the pathology added in our series of patients with aneurysm, the most frequent were: Aortic valvular disease, chronic smoking, systemic arterial hypertension and Marfan syndrome, coarctation of the aorta, coronary artery disease similar to that reported in world literature. (Ramirez-Vargas et al., 2003; Kouchoukos, 1996; Gelsomino et al., 2003; Miyairi et al, 2002; Tominaga et al., 2003; Kazui et al., 2002)

The complications that have been reported early as ventricular failure, ventricular arrhythmias and hemorrhage are similar to that reported in our series. In addition other authors report paraplegia, stroke, renal failure, myocardial infarction, and respiratory failure. (Gelsomino et al, 2003; Girardi et al, 2002; Tominaga et al, 2003).

The ejection fraction of the left ventricle in our series was from 20% to 78%, varying with the reported in another series with a greater average 65%. (Kouchoukos, 1996)

Probably due to the risks involved in elective repair, a large proportion of patients, approximately 25% are treated urgent due to acute symptoms (Coselli et al, 2000).

On this basis its very recommended the diagnose of aortic aneurysm rupture, monitor before a small aneurysm, found incidentally or through screening, until it reaches in size where the benefit of surgical repair outweighs the risks associated with such surgery. Always remember the possibility of aortic dissection in a patient with severe pain suggestive of acute myocardial infarction (AMI) but without clear electrocardiogram (ECG) findings. All patients with aortic dissection must be referred to a hospital immediately.

Finally, in the decision of surgical intervention we must consider the age of the patient, his state of health, their symptoms and the size of aneurysm (McKneally, 2001), or the reason why surgery is required. As an example to the above mentioned, in our experience there was need to operated a septuagenarian patient who had been treated with the placement of a mechanical valved graft by thrombosis of the same. This was an emergency procedure and was only made the thrombectomy with a good result and recovery for the patient (Careaga-Reyna et al., 2006).

Is very important to define the diagnosis of aortic dissection vs acute myocardial infarction in aortic dissection because thrombolysis is contraindicated.

5. Conclusion

With this brief presentation, we can conclude that aortic artery aneurysms are not a recent pathology. The frequency of cases has increased by the greater care of the physician in the clinical evaluation and the availability of technological resources. The aortic aneurysm is a complex pathology, current therapeutic options allow to offer more secure procedures, with less morbidity and even patients than before were not considered candidates for treatment by the presence of other diseases now after a complete evaluation can be included for open or endovascular surgical procedures.

6. References


- Bachet J, Guilmet D, Goudot B, Dreyfus G, Delentdecker P & Brodaty D. (1999). Antegrade cerebral perfusion with cold blood: a 13-year experience. *Annals of Thoracic Surgery*, Vol. 67, No. 6, (June, 1999), pp. 1891-1894, ISSN 0003-4975
- Bell R, Taylor P, Aukett M, Young CP, Anderson DR & Reidy JF. (2003) Endoluminal repair of aneurysms associated with coarctation. *Annals of Thoracic Surgery*, Vol.75, No. 2, (February, 2003), pp.530-533, ISSN 0003-4975
- Bengtsson H & Bergqvist D. (1993). Ruptured abdominal aortic aneurysm: A population-based study. *Journal of Vascular Surgery* Vol.18, No. 1 (July, 1993), pp. 74-80, ISSN 0741-5214
- Bickerstaff LK, Pairolero PC, Hollier LH, Melton LJ, VanPeenen HJ, Cherry KJ, Joyce JN & Lie JT. (1982). Thoracic aortic aneurysms: A population-based study. *Surgery* Vol.92 No. 6, (December, 1982), pp. 1103-1108.
- Cabrol C, Pavie A, Mesnildrey P, Gandjbakhch I, Laughlin L, Boys V & Corcos T. (1986). Long-term results with total replacement of the ascending aorta and reimplantation of the coronary arteries. *Journal of Thoracic and Cardiovascular Surgery* 1986; Vol.91, No. 1, (July, 1986), pp.17-25, ISSN 1524-0274
- Careaga RG, Ramírez CA, Ramírez CS, Salazar GD & Argüero SR. (2001). Derivación extracorpórea izquierda transoperatoria para la corrección de un aneurisma de la aorta torácica. *Revista Mexicana de Angiología*, Vol.29, (2001), pp.130-132.
- Careaga-Reyna G, Ramirez-Castaneda A, Ramirez-Castaneda S, Salazar-Garrido D & Argüero-Sanchez R. (2006). Tratamiento quirúrgico de la trombosis de un injerto valvulado mecánico. *Anales Medicos (Mexico)*, Vol. 51, No. 1, (Enero 2006), pp.33-35. ISSN 0185-3252
- Carias de Oliveira N, David TE, Ivanov J, Armstrong S, Eriksson MJ, Rakowski H & Webb G. (2003). Results of surgery for aortic root aneurysms in patients with Marfan syndrome. *Journal of Thoracic and Cardiovascular Surgery*, Vol.125, No. 4 (April, 2003), pp. 789-96, ISSN 1524-0274
- Chuter TAM, Gordon RL, Reilly LM, Pak LK & Messina LM. (2001). Multi-branched stent-graft for type III thoracoabdominal aortic aneurysm. *Journal of Vascular and Interventional Radiology*, Vol.12, No. 3 (March, 2001), pp. 391-392, ISSN 1051-0443
- Coady MA, Rizzo JA, Goldstein LJ & Elefteriades JA.(1999). Natural history, pathogenesis, and etiology of thoracic aortic aneurysms and dissections. *Cardiology Clinics*, Vol.17, (1999), pp. 615-635, ISSN 0733-8651

- Colombi P, Rossi C, Porrini M & Pellegrini A. (1983). Aneurysms involving the aortic arch. Report on thirteen surgically treated patients. *The Thoracic and Cardiovascular Surgeon*, Vol.31, No. 4, (August, 1983), 234-238, ISSN 0171-6425
- Cooley DA. (1999). Aortic aneurysm operations: past, present, and future. *Annals of Thoracic Surgery*, Vol.67, No. 6, (June, 1999), pp.1959-1962, ISSN 0003-4975
- Coselli JS, LeMaire SA, Miller CC, Schmittling ZC, Koksov C, Pagan J & Corlin PE. (2000). Mortality and paraplegia after thoracoabdominal aortic aneurysm repair: A risk factor analysis. *Annals of Thoracic Surgery*, Vol.69, No. 2, (February, 2000), pp.409-414, ISSN 0003-4975
- Crawford ES. (1974). Thoracoabdominal and abdominal aortic aneurysm involving renal, superior mesenteric and celiac arteries. *Annals of Surgery*, Vol.179, No. 5, (May, 1974), pp.763-772, ISSN 1528-1150
- Dake MD, Miller DC, Semba CP, Mitchell RS, Walker PJ & Liddell RP. (1994). Transluminal placement of endovascular stent-grafts for the treatment of descending thoracic aortic aneurysms. *New England Journal of Medicine*, Vol.331, No. 6 (December, 1994), pp. 1729-1734, ISSN 0028-4793
- David T & Feindel C. (1992). An aortic valve-sparing operation for patients with aortic incompetence and aneurysm of the ascending aorta. *Journal of Thoracic and Cardiovascular Surgery*, Vol.103, No. 7 (July, 1992), pp.617-622, ISSN 1524-0274
- David TE. (1997). Annuloaortic Ectasia. In: *Mastery of Cardiothoracic Surgery*, Kaiser LR, Kron IL, Spary TL, pp. 453-497 Lippincott-Raven Publishers, ISBN 978-0-7817-5309-1, USA.
- Deeb M, Williams D, Quint L, Monaghan HM & Shea MJ. (1999). Risk analysis for aortic surgery using hypothermic circulatory arrest with retrograde cerebral perfusion. *Annals of Thoracic Surgery*, Vol.67, No. 6 (June, 1999), pp. 1883-1886, ISSN 0003-4975
- Di Eusanio M, Tan E, Schepens M, Dossche K, Di Bartolomeo R, Pirangelo P & Morshair WD. (2003). Surgery for acute type A dissection using antegrade selective cerebral perfusion: Experience with 122 patients. *Annals of Thoracic Surgery*, Vol. 75, No. 2, (February, 2003), pp.514-519, ISSN 0003-4975
- Dossche K, Schepens M, Morshuis W, Muysoms F, Langemeljer JJ & Vermeulen EE. (1999). Antegrade selective cerebral perfusion in operations on the proximal thoracic aorta. *Annals of Thoracic Surgery*, Vol.67, No.6 (June, 1999), pp. 1904-1910, ISSN 0003-4975
- Ergin M, Spielvogel D, Apaydin A, Lansman SL, McCullough JN, Gallo JD & Griep RB. (1999). Surgical treatment of the dilated ascending aorta: When and how? *Annals of Thoracic Surgery*, Vol.67, No. 6, (June, 1999), pp.1834-1839, ISSN 0003-4975
- Galajda Z, Szentkirályi I & Péterffy Á. (2003). Brachial artery cannulation in type A aortic dissection operations. *Journal of Thoracic and Cardiovascular Surgery*, Vol.125, No. 2, (February, 2003), pp.407-409, ISSN 1524-0274
- Gelsomino S, Frassani R, Da Col P, Morocutti G, Masullo G, Spedicato L & Livi U. (2003). A long-term experience with the Cabrol root replacement technique for the management of ascending aortic aneurysms and dissections. *Annals of Thoracic Surgery*, Vol. 75, No. 1, (January, 2003), pp.126-31, ISSN 0003-4975
- Girardi N, Krieger H, Altorki NK, Mack CA, Lee LY & Isom OW. (2002). Ruptured descending and thoracoabdominal aortic aneurysms. *Annals of Thoracic Surgery*, Vol. 74, No. 10 (October, 2002), pp.1066-70, ISSN 0003-4975

- Greenberg R & Rischer W. (1998). Toma de decisiones clínicas y métodos operatorios en caso de aneurismas aórticos torácicos. *Clínicas Quirúrgicas de Norteamérica*, Vol.5, (1998), pp. 763-782, ISSN 0039-6109
- Griep RB. (2003). Cerebral protection during aortic arch surgery. *Journal of Thoracic and Cardiovascular Surgery*, Vol.125, No.3 (March, 2003), pp. 36-38, ISSN 1524-0274
- Jacobs MJ & Mess WH. (2003). The role of motor evoked potential monitoring in operative management of type I and type II thoracoabdominal aortic aneurysms. *Seminars of Thoracic and Cardiovascular Surgery*, Vol.15, No. 4, (October, 2003), pp. 353-364, ISSN 1522-9645
- Johansson G, Markstrom U & Swedenborg J. (1995). Ruptured thoracic aortic aneurysms: A study of incidence and mortality rates. *Journal of Vascular Surgery*, Vol. 21, No. 6, (June, 1995), pp.985-988, ISSN 0741-5214
- Joyce JW, Fairbairn JF, Kincaid OW & Juergens JL. (1964). Aneurysms of the thoracic aorta. A clinical study with special reference to prognosis. *Circulation*, Vol. 29, No. 2, (February, 1964), pp. 176-181, ISSN 1346-9843
- Karmy-Jones R, Carter Y, Meissner M & Mulligan MS. (2001). Choice of venous cannulation for bypass during repair of traumatic rupture of the aorta. *Annals of Thoracic Surgery*, Vol.71, No.1, (January, 2001), pp.39-42, ISSN 0003-4975
- Kato M, Kuratani T, Kaneko M, Kyo S & Ohnishi K. (2002). The results of total arch graft implantation with open stent-graft placement for type A aortic dissection. *Journal of Thoracic and Cardiovascular Surgery*, Vol. 124, No.9, (September, 2002), pp.531-40, ISSN 1524-0274
- Kay GL, Cooley DA, Livesay JJ, Reardon MJ & Duncan JM. (1986). Surgical repair of aneurysms involving the distal aortic arch. *Journal of Thoracic and Cardiovascular Surgery*, Vol.91, No.7, (July, 1986), pp.397-404, ISSN 1524-0274
- Kazui T, Washiyama N, Basher AHM, Terada H, Suzuki T, Ohkura K & Yamashita K. (2002). Surgical outcome of acute type A aortic dissection: Analysis of risk factors. *Annals of Thoracic Surgery*, Vol. 74, No. 7, (July, 2002), pp.75-81, ISSN 0003-4975
- Knyshev GV, Sitar LL, Glagola MD & Atamanyuk MY. (1996). Aortic aneurysms at the site of the repair coarctation of the aorta: of review of 48 patients. *Annals of Thoracic Surgery*, Vol.61, No. 3, (March, 1996), pp.935-939, ISSN 0003-4975
- Kouchoukos NT. (1996). Aneurysms of the ascending aorta. In: *Glenn's Thoracic and Cardiovascular Surgery* 6th ed, Baue AE, Geha AS, Hammond GL, Laks H & Naunheim KS, pp. 2225-2237, Stanford, CT, Appleton Lange, ISBN 0-8385-3134-2, USA.
- Kouchoukos NT, Blackstone EH, Doty DB, Hanley FL & Karp RB. (2003). Coarctation of the aorta and interrupted aortic arch. In: *Kirklin/Barrat-Boyes Cardiac Surgery*, Vol. 2. 3rd ed, pp.1315-1375, Churchill Livingstone, ISBN 0-443-07526-3, USA.
- LaRoy LL, Cormier PJ, Matalon TA, Patel SK, Turner DA & Silver B. (1989). Imaging of abdominal aortic aneurysms. *AJR American Journal of Roentgenology*, Vol.152, No.4, (April, 1989), pp.785-792, ISSN 0361-803X
- Lederle FA, Kane RL, MacDonald R & Wilt TJ. (2007). Systematic review: repair of unruptured abdominal aortic aneurysm. *Annals of Internal Medicine*, Vol. 146, No.10, (May 2007), pp.735-741, ISSN 0003-4819
- Lepore V, Lönn L, Delle M, Bugge M, Jeppsson A, Kjellman U, Radberg G & Risberg B. (2002). Endograft therapy for aneurysms diseases of the descending aorta; results in

- 43 consecutive patients. *Journal of Endovascular Therapy*, Vol. 9, No.6, (December, 2002), pp. 829–837, ISSN 1526-6028
- Levine KA, Bao KS & Silver AW. (1968). Repair of aortic coarctation and post-stenotic aneurysm in a 63-year-old woman. *Journal of Thoracic and Cardiovascular Surgery*, Vol. 55, No.7, (July, 1968), pp. 732-736, ISSN 1524-0274
- Lönn L, Delle M, Falkenberg M, Lepore V, Klingenstierna H, Rädberg G & Risberg B. (2003). Endovascular treatment of type B thoracic aortic dissections. *Journal of Cardiac Surgery*, Vol.18, No. 6, (November, 2003), pp.539–544, ISSN (on line) 1540-8191
- Massih TA, Vouhé PR, Mauriat P, Mousseaux E, Sidi D & Bonnet D. (2002). Replacement of the ascending aorta in children: A series of fourteen patients. *Journal of Thoracic and Cardiovascular Surgery*, Vol.124, No.8, (August, 2002), pp.411-413, ISSN 1524-0274
- McNamara JJ & Pressler VM. (1978). Natural history of arteriosclerotic thoracic aortic aneurysms. *Annals of Thoracic Surgery*, Vol.26, No. 7, (July, 1978), pp.468–473, ISSN 0003-4975
- McKneally MF. (2001). We don't do that here: Reflections on the Siena experience with dissecting aneurysms of the thoracic aorta in octogenarians. *Journal of Thoracic and Cardiovascular Surgery*, Vol.121, No. 2, (February, 2001), pp.202-203, ISSN 1524-0274
- Melissano G, Civilini E, Marrocco-Trischitta MM & Chiesa R. (2004). Hybrid endovascular and off-pump open surgical treatment for synchronous aneurysms of the aortic arch, brachiocephalic trunk and abdominal aorta. *Texas Heart Institute Journal*, Vol.31, No.3, (August, 2004), pp.283-287, ISSN 0730-2347
- Meszaros I, Morocz J, Szilavi J, Schmidt J, Tornosi L, Nafy L & Szep L.(2000). Epidemiology and clinicopathology of aortic dissection. *Chest*, Vol.117, No. 5 (May, 2000), pp.1271-1278, ISSN 0012-3692
- Minatoya K, Karck M, Szpakowski E, Harringer W & Haverich A. (2003). Ascending aortic cannulation for Stanford type A acute aortic dissection: another option. *Journal of Thoracic and Cardiovascular Surgery*, Vol.125, No. 4, (April, 2003), pp.952-953, ISSN 1524-0274
- Miyairi T, Kotsuka Y, Ezure M, Ono M, Morota T, Kubota H, Shibati K, Ueno K & Takamoto S. (2002). Open stent-grafting for aortic arch aneurysm is associated with increased risk of paraplegia. *Annals of Thoracic Surgery*, Vol. 74, No.1, (July, 2002), pp 83-89, ISSN 0003-4975
- Murray GF & Young WG Jr. (1976). Thoracic aneurysmectomy utilizing direct left ventriculofemoral shunt (TDMAC-Heparin) bypass. *Annals of Thoracic Surgery*, Vol. 21, No.1, (July, 1976), pp.26-29, ISSN 0003-4975
- Oberwalder J, Tilz G & Rigler B. (2003). Spontaneous acute type A aortic dissection as a result of autoimmune aortitis without previous aortic dilatation in a 43-year-old man. *Journal of Thoracic and Cardiovascular Surgery*, Vol.125, No.2, (February, 2003), pp. 413, ISSN 1524-0274
- Oster H, Schöllhorn J, Züchner & Leitz H. (1983). Thermographic evaluation of myocardial temperature during infusion of cold cardioplegia. *Thoracic and Cardiovascular Surgeon*, Vol.31, No.1, (February, 1983), pp. 31-34, ISSN 0171-6425
- Parks WJ, Ngo TD, Plauth WH Jr, Bank ER, Sheppard SK, Pettigrew RI & Williams WH. (1995). Incidence of aneurysm formation after Dacron patch angioplasty repair for coarctation of the aorta: long-term results and assessment utilizing magnetic

- resonance angiography with three dimensional surface rendering. *Journal of the American College of Cardiology*, Vol.26, No.1, (July, 1995), pp.266-271, ISSN 0735-1097
- Powell JT & Greenhalgh RM. (2003). Small abdominal aortic aneurysms. *New England Journal of Medicine*, Vol. 348, No. 19, (May 2003), pp.1895-901, ISSN 0028-4793
- Ramirez-Vargas A, Careaga-Reyna G, Tellez-Luna S & Argüero-Sanchez R. (2003). Tratamiento quirúrgico de los aneurismas de la aorta torácica. *Revista Mexicana de Cardiología*, Vol. 14, No. 4, (December, 2003), pp. 118-127, ISSN 0188-2198
- Risberg B & Lars Lönn L. (2007) Chapter 1 Etiology and pathogenesis of aortic disease, In: *Advanced Endovascular Therapy of Aortic Disease*, Lumsden AB, Lin PH, Chen C & Parodi JC, pp. 3-10, Blackwell Publishing, ISBN: 978-1-4051-5570-0, Massachusetts, USA.
- Safi HJ. (2007), Chapter 3 Thoracic aortic aneurysms: classification, incidence, etiology, natural history, and results. In: *Advanced Endovascular Therapy of Aortic Disease*, Lumsden AB, Lin PH, Chen C, Parodi JC, pp. 25-30, Blackwell Publishing, ISBN: 978-1-4051-5570-0, Massachusetts, USA.
- Saiki N, Ishimara S, Kawaguchi S, Shimazaki T, Yokoi Y & Obitsu Y.(2003). Endografting facilitated by axillary-axillary bypass for distal arch aneurysm after left internal thoracic artery to left anterior descending artery bypass surgery. *Journal of Thoracic and Cardiovascular Surgery*, Vol.125, No. 4, (April, 2003), pp.950-952, ISSN 1524-0274
- Schulte H, Bircks W, Frenzel H, Horstkotte D, Jungblut R & Oubari M. (1983). Patch-graft enlargement of the aortic root using autologous pericardium (Long-term results). *Thoracic and Cardiovascular Surgeon*, Vol.31, No. 4, (August, 1983), pp.219-223, ISSN 0171-6425
- Schuster SR & Gross RE. (1962). Surgery for coarctation of the aorta: a review of 500 cases. *Journal of Thoracic and Cardiovascular Surgery*, Vol.43, No.1, (January, 1962), pp.54-70, ISSN 1524-0274
- Svensson LG, Crawford ES, Hess KR, Coselli JS & Safi HJ. (1993). Experience with 1509 patients undergoing thoracoabdominal aortic operations. *Journal of Vascular Surgery*, Vol.17, No.2, (February, 1993), pp.357-370, ISSN 0741-5214
- Tominaga R, Kurisu K, Ochiai Y, Nakashima A, Masuda M, Morita S & Yasui H. (2003). Total aortic arch replacement through the I-incision approach. *Annals of Thoracic Surgery*, Vol.75, No.1, (January, 2003), pp.121-125, ISSN 0003-4975
- Verhoeven EL, Zeebregts CJ, Kapma MR, Tielliu IF, Prins TR & van den Dungen JJ.(2005). Fenestrated and branched endovascular techniques for thoracoabdominal aneurysm repair. *Journal of Cardiovascular Surgery (Torino)*, Vol.46, No.2, (April, 2005), pp.131-140, ISSN 0021-9509
- Volodos ML, Karpovich IP, Troyan VI, Kalashnikova YV, Shekhanin VE, Ternyuk NE, Neoreta AS, Ustinov NI & Yakovenko LF. (1991). Clinical experience of the use of self-fixating synthetic prosthesis for remote endoprosthesis of the thoracic and abdominal aorta and iliac arteries through the femoral artery and as intraoperative endoprosthesis for aortic reconstruction. *Vasa*, Vol.33 (Suppl), (1991), pp.93-95.
- Von Fricken K (2002). Capitulo 44. Aneurismas de la aorta torácica. In: *Secretos de la cirugía cardiaca*. Soltoski PR, Karamanoukian HL, Salerno TA, pp. 193-196. McGraw-Hill Interamericana, ISBN 970-10-3610-7, Mexico.



Diagnosis and Treatment of Abdominal and Thoracic Aortic Aneurysms Including the Ascending Aorta and the Aortic Arch

Edited by Prof. Reinhart Grundmann

ISBN 978-953-307-524-2

Hard cover, 208 pages

Publisher InTech

Published online 22, June, 2011

Published in print edition June, 2011

This book considers diagnosis and treatment of abdominal and thoracic aortic aneurysms. It addresses vascular and cardiothoracic surgeons and interventional radiologists, but also anyone engaged in vascular medicine. The book focuses amongst other things on operations in the ascending aorta and the aortic arch. Surgical procedures in this area have received increasing attention in the last few years and have been subjected to several modifications. Especially the development of interventional radiological endovascular techniques that reduce the invasive nature of surgery as well as complication rates led to rapid advancements. Thoracoabdominal aortic aneurysm (TAAA) repair still remains a challenging operation since it necessitates extended exposure of the aorta and reimplantation of the vital aortic branches. Among possible postoperative complications, spinal cord injury (SCI) seems one of the most formidable morbidities. Strategies for TAAA repair and the best and most reasonable approach to prevent SCI after TAAA repair are presented.

How to reference

In order to correctly reference this scholarly work, feel free to copy and paste the following:

Guillermo Careaga-Reyna (2011). Definitions, History and General Considerations Related to the Aortic Aneurysms, *Diagnosis and Treatment of Abdominal and Thoracic Aortic Aneurysms Including the Ascending Aorta and the Aortic Arch*, Prof. Reinhart Grundmann (Ed.), ISBN: 978-953-307-524-2, InTech, Available from: <http://www.intechopen.com/books/diagnosis-and-treatment-of-abdominal-and-thoracic-aortic-aneurysms-including-the-ascending-aorta-and-the-aortic-arch/definitions-history-and-general-considerations-related-to-the-aortic-aneurysms>

INTECH
open science | open minds

InTech Europe

University Campus STeP Ri
Slavka Krautzeka 83/A
51000 Rijeka, Croatia
Phone: +385 (51) 770 447
Fax: +385 (51) 686 166
www.intechopen.com

InTech China

Unit 405, Office Block, Hotel Equatorial Shanghai
No.65, Yan An Road (West), Shanghai, 200040, China
中国上海市延安西路65号上海国际贵都大饭店办公楼405单元
Phone: +86-21-62489820
Fax: +86-21-62489821

© 2011 The Author(s). Licensee IntechOpen. This is an open access article distributed under the terms of the [Creative Commons Attribution 3.0 License](#), which permits unrestricted use, distribution, and reproduction in any medium, provided the original work is properly cited.